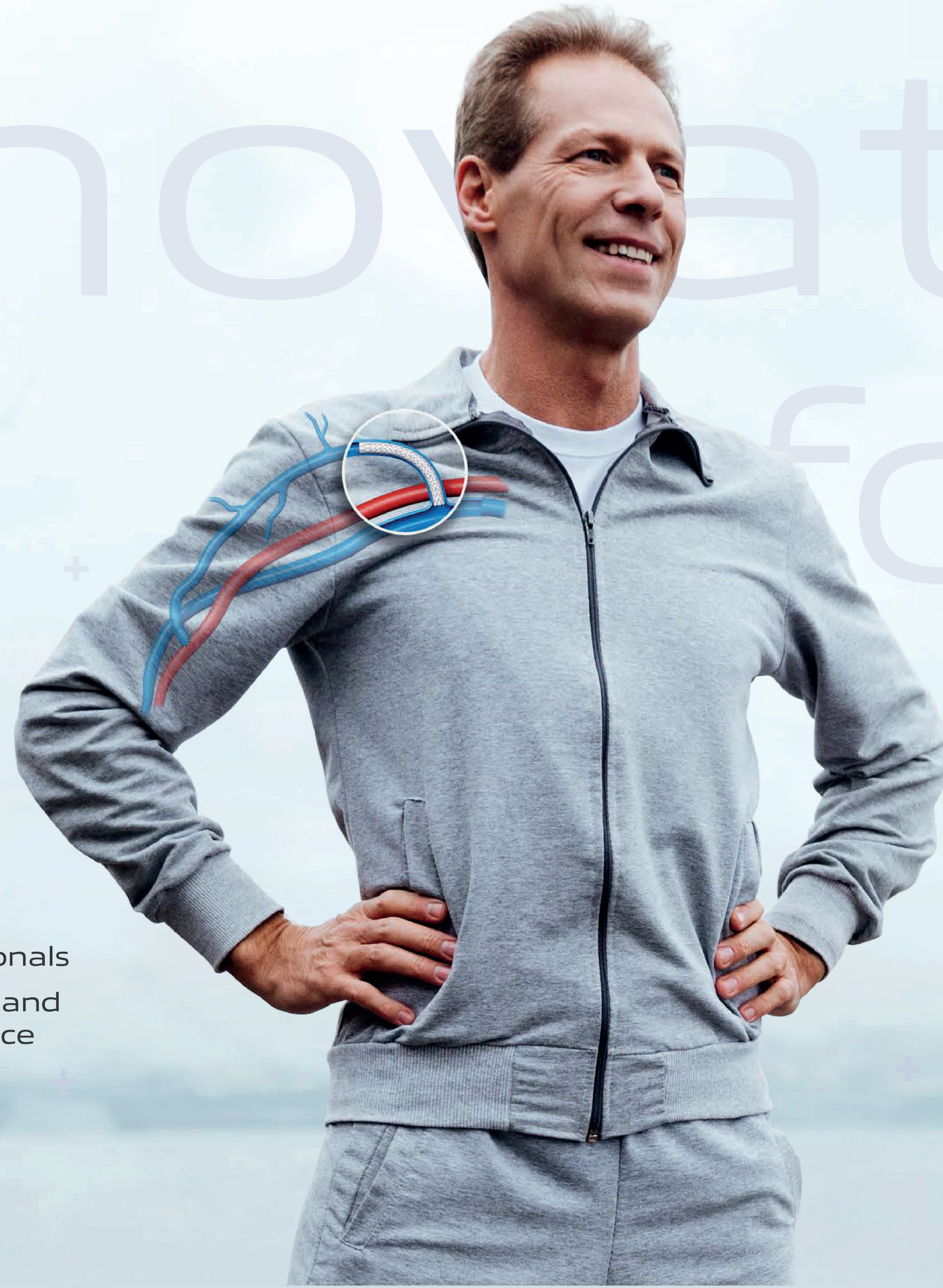

CE
2265



SOLARIS[®]
SELF-EXPANDING

Innovation for life



MISSION

- Improve patients' quality of life
- Provide effective and Innovative solutions for healthcare professionals
- Make our customers feel unique and have outstanding customer service



PRESENT IN MORE THAN 45 COUNTRIES

SCITECH Medical is a minimally invasive medical device company that was founded over 18 years ago and is currently present in more than 45 countries. Through state-of-the-art technology and the use of the highest quality materials, tested and proven by the most rigorous international standards and clinical trials, SCITECH manufactures products that empower healthcare professionals to save or improve the quality of life of their patients

For further information visit the website: scitechmed.com



The SOLARIS is a flexible, self-expanding endograft, comprised of a thin, multi-direction, durable electrospinning PTFE membrane encapsulating a Nitinol stent structure.



The device has been **engineered to effectively cover and instantaneously seal off** diseased tissue with a high multidirectional resistance membrane, providing an endoluminal bypass option for **physicians faced with complex lesions**. Its design provides high flexibility without compromising the requirement length, balanced radial force and low shortening rate. **The pull-back hydrophilic delivery system** provides superior navigability, and its anti-jumping system guarantees accurate deployment during the procedure.

High Flexibility
Precision
Balanced Radial Strength
Minimal Shortening

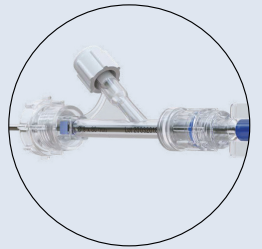SOLARIS
SELF-EXPANDING



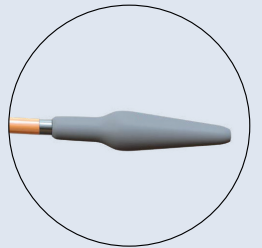
Multidirectional
resistance strength with
instantaneous sealing

+


Pull-back
delivery
system




Atraumatic
flexible tip




Anti-jumping
feature



Hydrophilic
coating



3 Tantalum
marker bands
(Distal/Proximal)




+

+

SOLARIS
HIGH FLEXIBILITY


CE
2265



High Flexibility

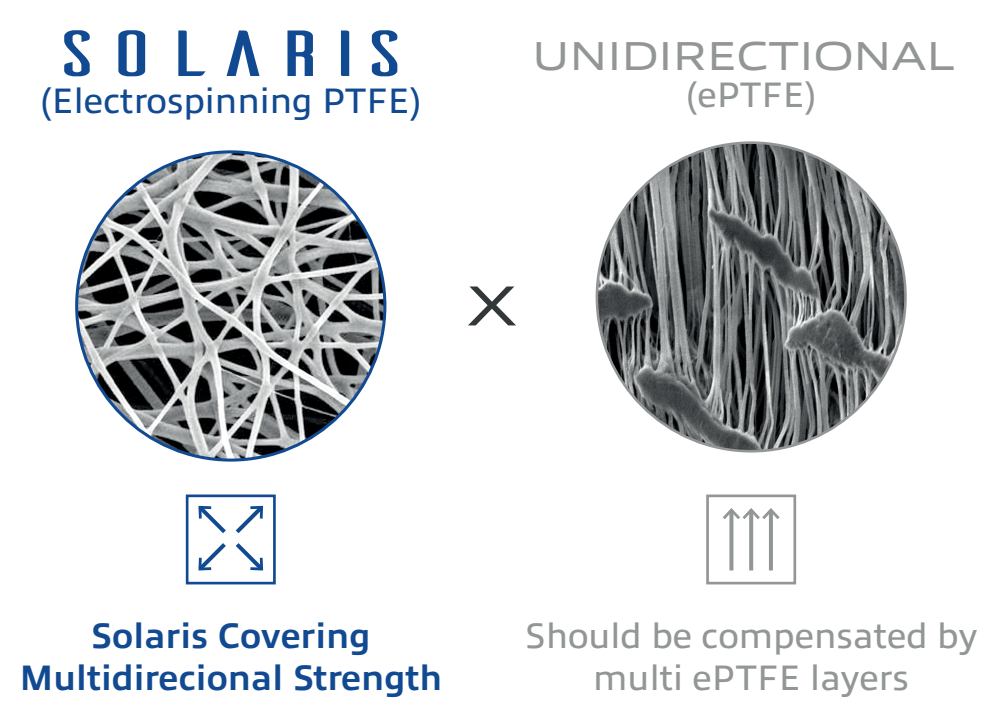
The **Solaris Endograft** is made from a laser cut Nitinol alloy. Due to its design, which maintains a distance from one cell to another, the product has high flexibility.

ELECTROSPINNING MEMBRANE




High strength and elasticity electrospinning PTFE Membrane
The Solaris Endograft is encapsulated both externally and internally by a thin PTFE membrane, produced by electrospinning process.
Proven in bench tests, the Solaris Endograft membrane has high resilience and elasticity.

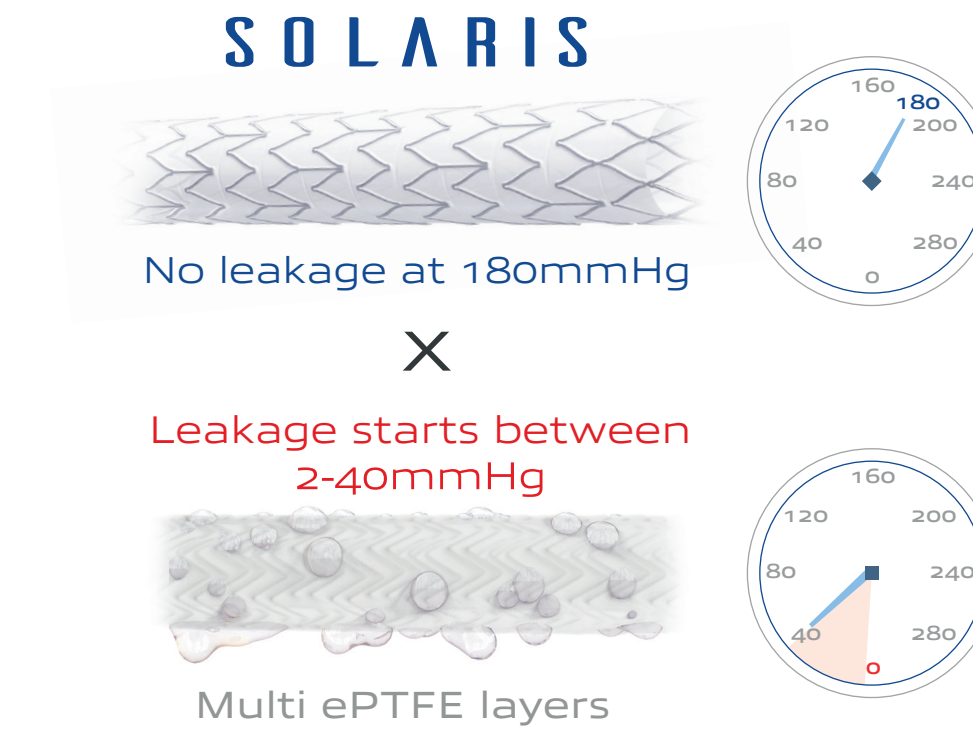
Membrane Characteristic



Perforation Test

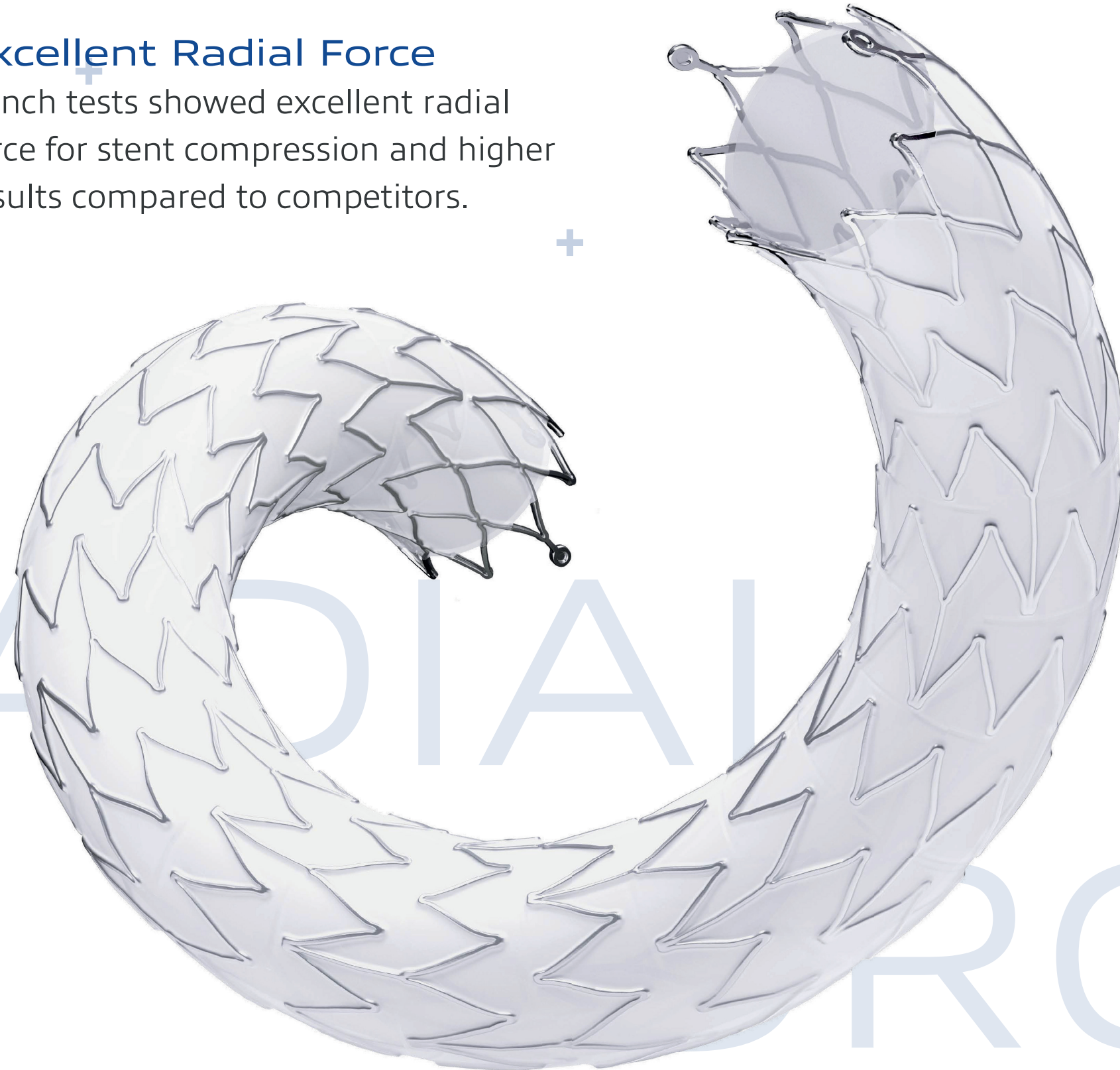


Permeability Test




Excellent Radial Force

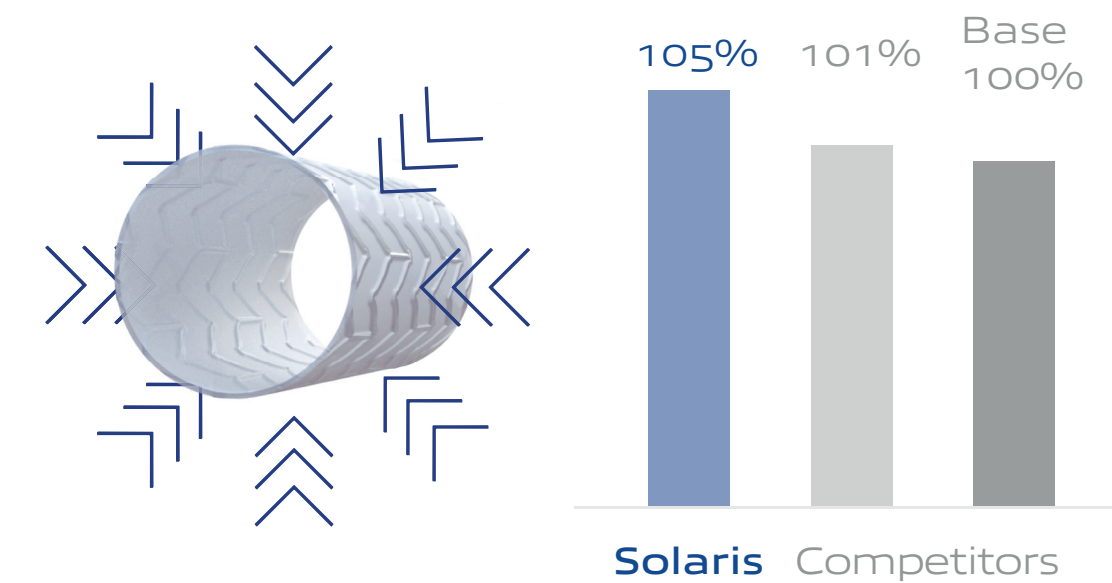
Bench tests showed excellent radial force for stent compression and higher results compared to competitors.



Local crush test for 2mm compression*



Radial force for 1mm compression



All tests carried out in Scitech labs for same stent sizes / *9mm stent diameter.

VERY GOOD RADIOPACITY

VERY GOOD RADIOPACITY

VERY GOOD RADIOPACITY

Radiopacity

Very Good Radiopacity

3 Tantalum Marker Bands (Distal/Proximal)

3 radiopaque tantalum marks were incorporated at 2mm from the PTFE on each side, which guarantee the product's visibility during the procedure.




Precise Hydrophilic Delivery System

Solaris pull-back hydrophilic delivery system provides superior navigability and accurate deployment during the procedure. Its braided hydrophilic covered catheter guarantees 75% reduction in force for navigation, prevents the system from kinking and increases the accuracy for accessing even more complex lesions. The delivery system has excellent radiopacity due to anti-jumping system, its atraumatic soft tip and two radiopaque markers on the braided sheath and on the external catheter.

VERY GOOD RADIOPACITY

VERY GOOD RADIOPACITY

BRAIDED SHAFT



HYDROPHILIC COATING

The hydrophilic delivery system allows a smoother positioning and precise implantation.

ANTI-JUMPING SYSTEM

The anti-jumping system prevents unexpected stent delivery.

ATRAUMATIC FLEXIBLE TIP

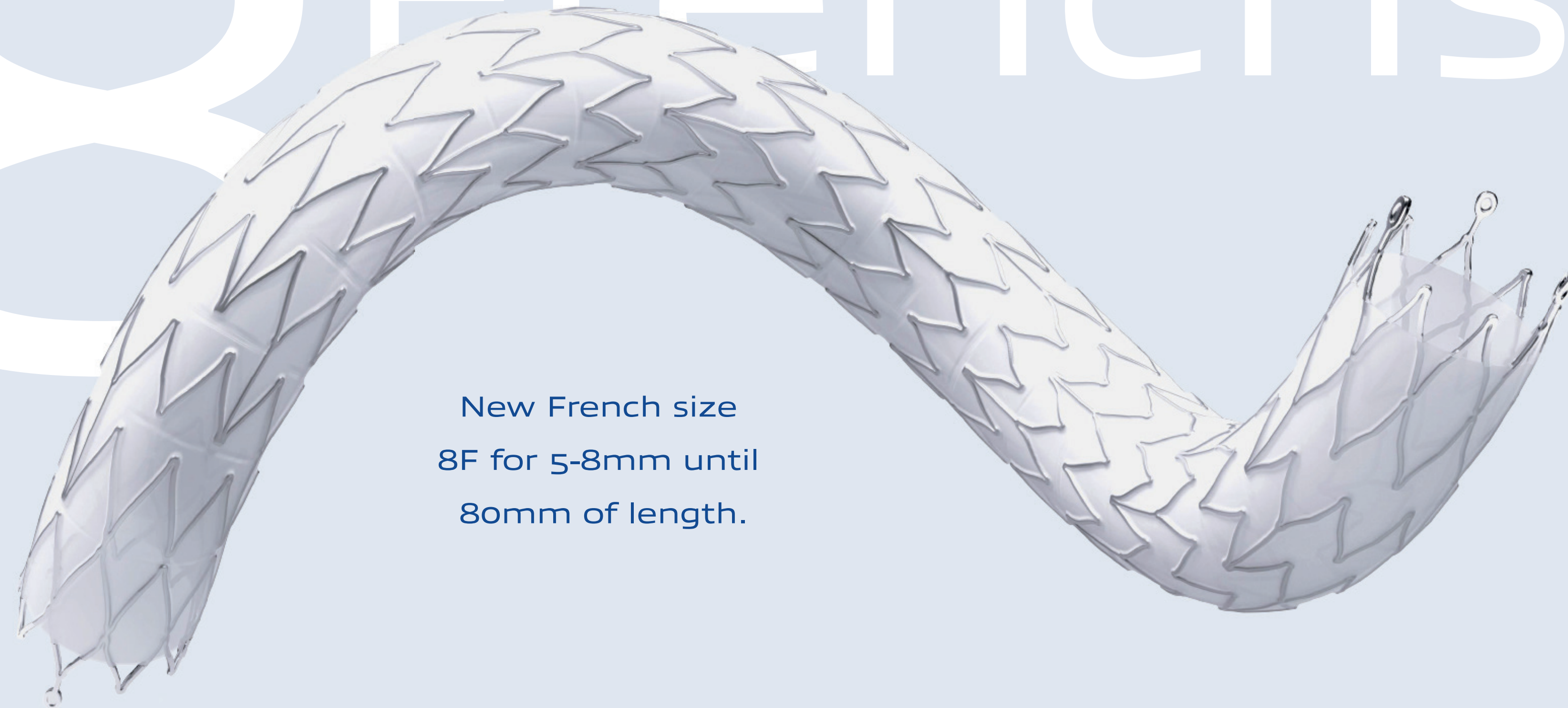A radiopaque atraumatic soft tip was incorporated at the distal edge of the delivery system.



SOLARIS
NEW FRENCH SIZE

CE
2265

8 Frenchs



New French size
8F for 5-8mm until
80mm of length.

Treatment of Subocclusive Atherosclerotic Lesion of the Left Subclavian Artery with Covered Stent

Prof. Dr. Paulo Eduardo Ocke Reis

CASE REPORT:

A 67-year-old female patient complaining of left upper limb (LUL) claudication reported limitation of simple activities such as brushing hair or washing hands. She presented worsening pain and numbness complaint of the LUL despite the clinical treatment. On physical examination, the absence of left brachial, radial and ulnar pulses was noticed. The angiotomography images (Figures I and II) confirmed the subocclusion of the left subclavian artery and a high degree of calcification of the lesion in the proximal segment of the artery.

TREATMENT:

After confirming the diagnosis, we indicated an endovascular procedure

with puncture access to the right femoral artery and revascularization of the left subclavian artery with a covered Solaris® stent.

Demonstration before and after delivery of the covered stent (Figures III, IV, V). Six-month follow-up with angiotomography (figure VI).

CONCLUSION:

The Solaris® covered stent showed excellent navigation, delivery and precision in a sub-occluded and calcified artery. The immediate radiological and clinical result was satisfactory in the brachial, radial and ulnar arteries, with medium term broad pulses observed during patient follow-up.

FIGURE I

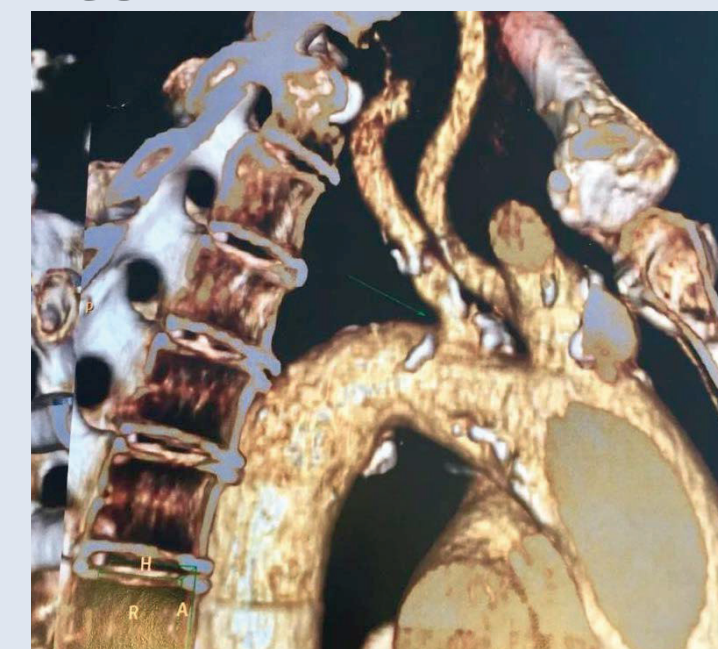
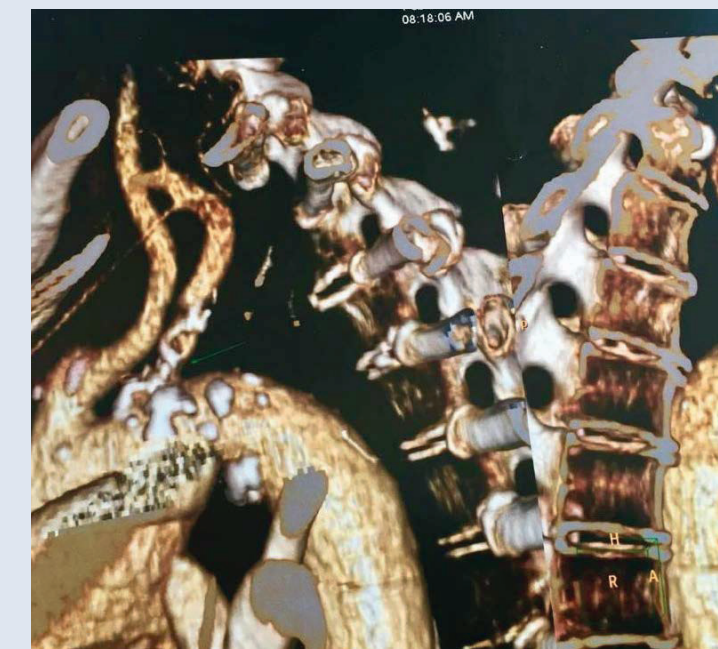


FIGURE II



Figures I and II - A pre-procedure angiotomography of the left subclavian artery confirming subocclusion and calcification of the artery.

FIGURE III

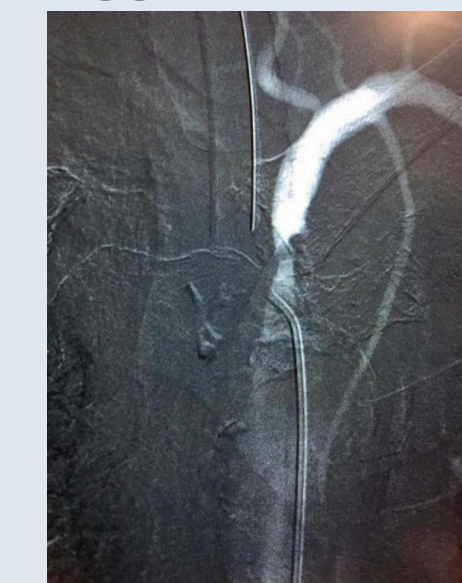
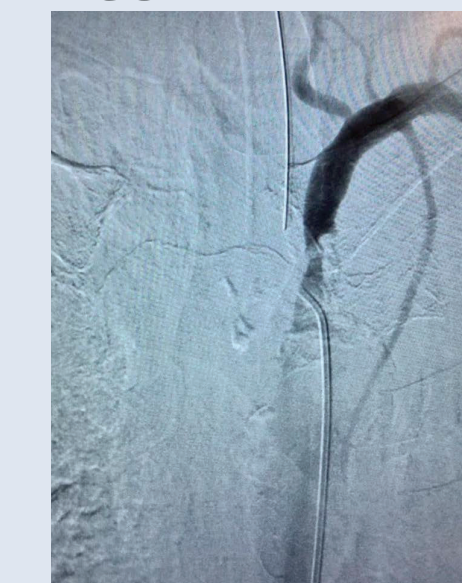
FIGURE IV

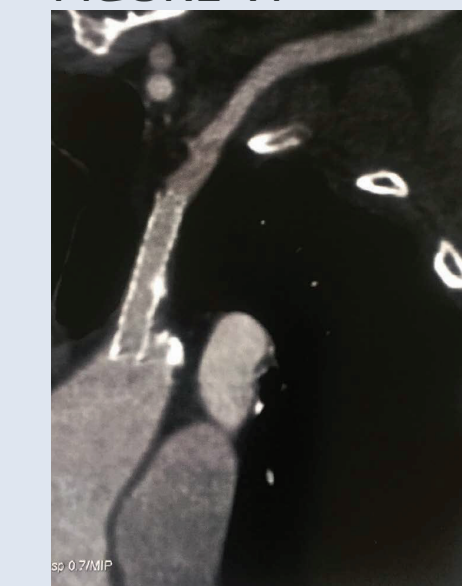


Figures III and IV - After the right femoral access, preoperative arteriography confirms a high degree of stenosis and an irregular calcified ostial atherosclerotic plaque.

FIGURE V

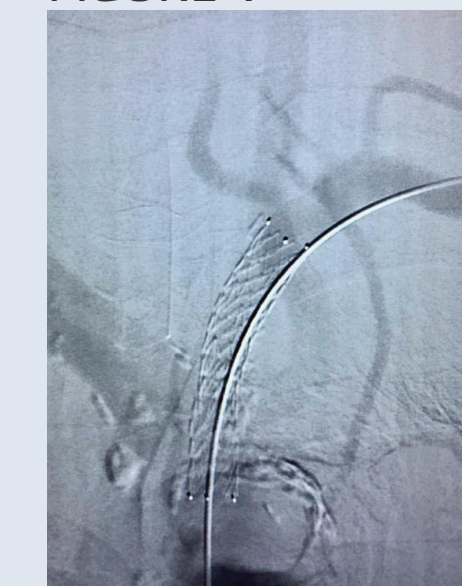

FIGURE VI



Figures V and VI - Final preoperative control and angiotomography after six months with excellent results. Lesion treatment and delivery of Solaris® 8x40mm safely and efficiently.

Solaris Stent Graft implant in the treatment of a failed basilica loop arteriovenous fistula due to swing point stenosis.

Dr. Leonardo Harduin

BACKGROUND:

A 29-year-old female patient with SAH, SLE and CRF on hemodialysis for 8 months through a basilica loop arteriovenous fistula in the left arm. She started feeling pain about thirty days ago during hemodialysis sessions, with increased venous resistance and increased bleeding time after hemodialysis sessions. She was admitted to the emergency room with disappearance of the fremitus in the AVF, hardening and local hyperemia, pain and puncture of the AVF with the release of multiple clots, compatible with access

thrombosis. A color doppler ultrasound showed thrombosis of the entire basilic vein from the anastomosis with the brachial artery to the outflow in the axillary vein.

METHODS:

Access through dissection of the arteriovenous fistula. Thrombectomy with Fogarty 4F catheter. Diagnostic phlebography showed 90% stenosis at the swing point. Recanalization of the stenotic segment and 9F introducer implant. Pre-dilation of the stenosed segment with

a 7x30mm high pressure balloon. Preoperative phlebography with severe residual stenosis. Solaris 9x60mm Stent Graft implant and accommodation with a 9x30mm high pressure balloon.

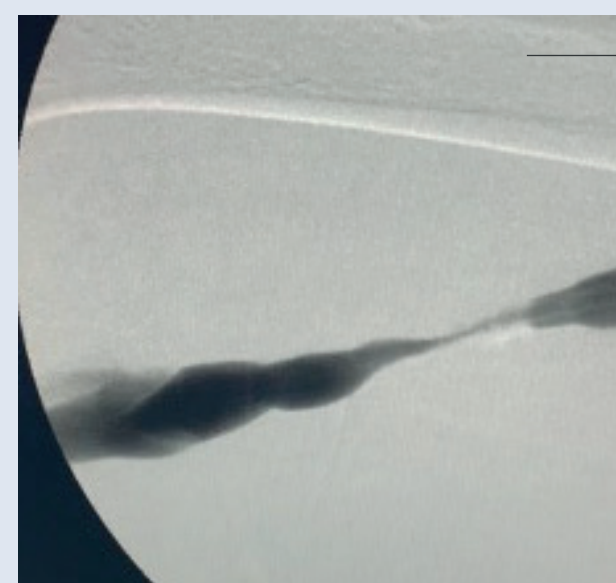
RESULTS:

Control phlebography with good results and without residual stenosis or folds. Fremitus at the end of the 4+/4+ procedure. Hemodialysis was performed by the AVF immediately after the procedure. Control color Doppler ultrasound (30 days) demonstrating the patency of the stent and

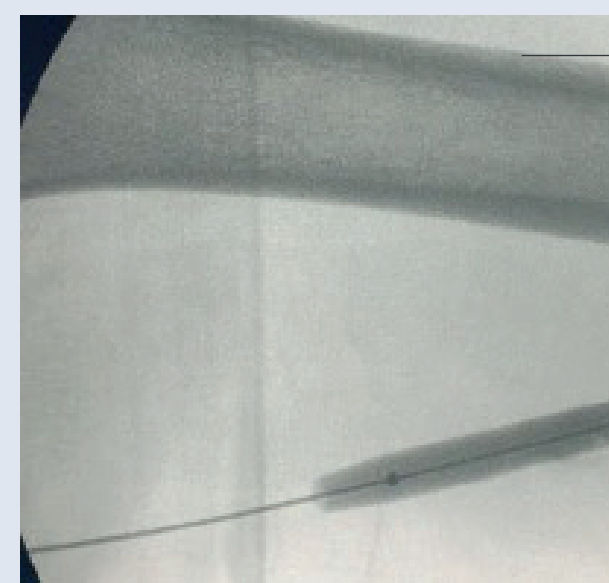
AVF flow volume of 1099 ml/min. Control phlebography at 6 months showing patent Stent Graft without stenosis.

CONCLUSION:

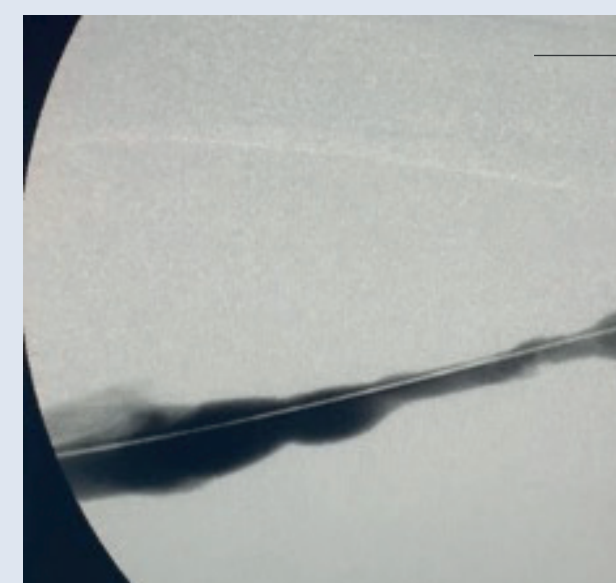
The use of the Solaris Stent Graft in the treatment of swing point lesions of the transposed basilic vein in failure was safe and effective, leading to an improvement in the quality of dialysis and maintenance of the access patency.



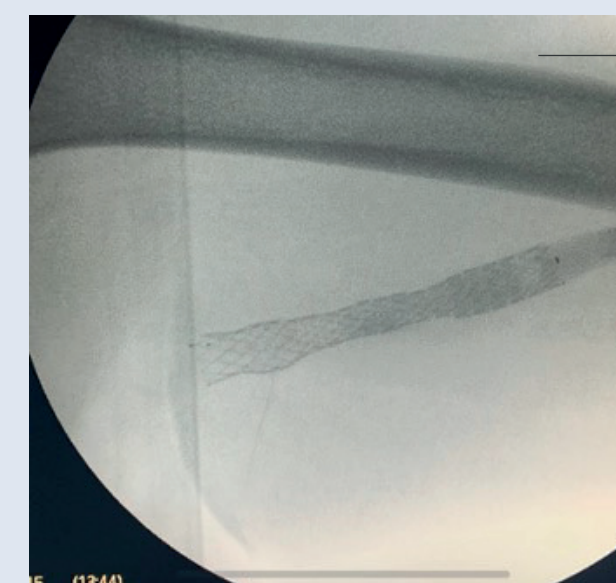90% stenosis at Swing point.



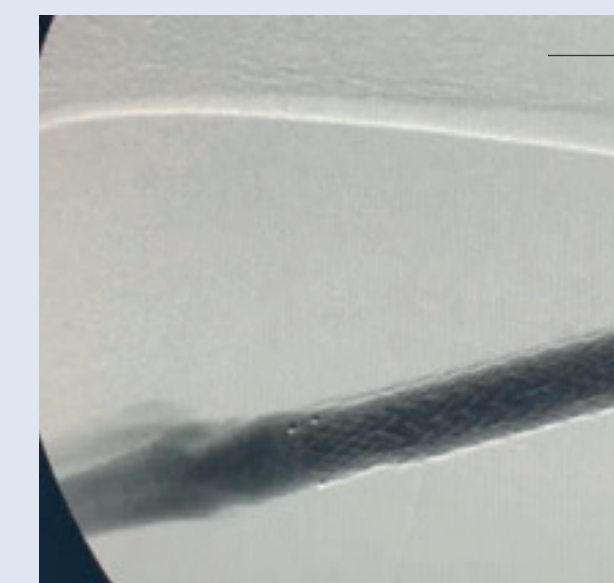
Angioplasty with a 7x30mm high pressure balloon.



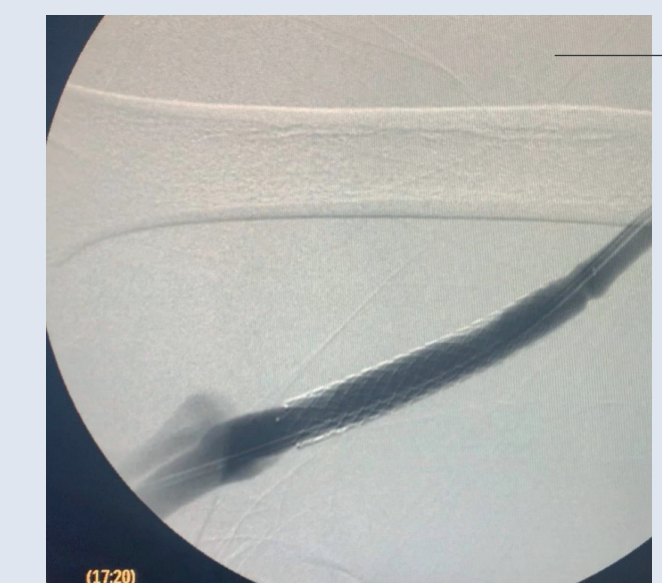Preoperative phlebography with severe residual stenosis.



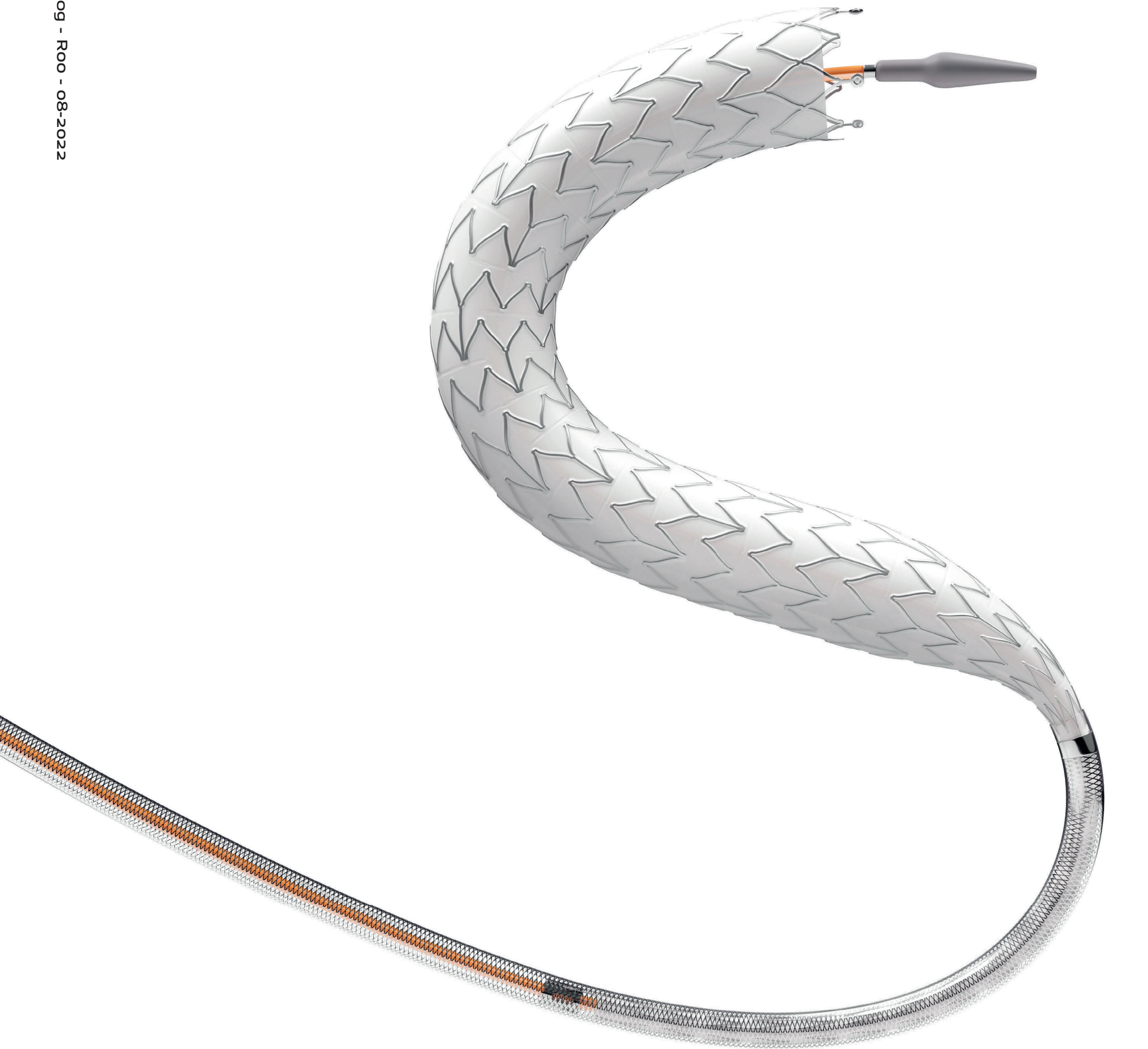
9x60mm Solaris Stent Graft implant.



Control phlebography without residual stenosis and with satisfactory result after post ballooning with a 9x30mm high pressure balloon.



Control phlebography at 6 months via femoral access demonstrating the patent Solaris stent graft without fractures.



Diameter	Length							
	40mm		60mm		80mm		100mm	
	Ref	∅	Ref	∅	Ref	∅	Ref	∅
5	128442	8F	128443	8F	128444	8F	128445	8F
6	128446	8F	128447	8F	128448	8F	128438	9F
7	128449	8F	128450	8F	128451	8F	128439	9F
8	128943	8F	128944	8F	128945	8F	128440	9F
9	128099	9F	128100	9F	128101	9F	128441	9F

DELIVERY SYSTEM (LENGTH): 130CM

